



Functional Appliance can Improve the TMJ Disk Displacement

Wang Jing*, Huona, Caichuan and Xululu

Orthodontics Department, The First Medical Center of PLA General Hospital, Beijing, China

Citation: Wang jing (2025) Functional Appliance can Improve the TMJ Disk Displacement. J. of Inn Clin Trail Case Reports 1(2), 1-3. WMJ/JCTC-116

Abstract

To evaluate the clinical treatment effect of functional appliance on disc displacement with reduction (DDwR), twenty-three patients were selected. During the treatment, patients underwent specialist temporomandibular joint examination of MRI. We found that the functional appliance can improve the disc displacement, joint clicking, reduce the joint effusion effectively, and promote regeneration for early condylar absorption. The treatment effect to DDwR of disc displacement is better than to DDwoR.

***Corresponding author:** Wang jing, Orthodontics Department, The First Medical Center of PLA General Hospital, Beijing, China.

Submitted: 20.08.2025

Accepted: 25.08.2025

Published: 30.08.2025

Keywords: Functional Appliance, TMD, Disc, Reposition, Effusion

Introduction

Temporomandibular joint disorders (TMD) are common diseases of the oral and maxillofacial system. Among the TMD classification, disc displacement with reduction (DDwR) is more common, the clinical manifestations are clicking when opening and closing, abnormal opening, and some patients have pain and discomfort [1]. At this time, the internal structure of the temporomandibular joint (TMJ) has been

and the articular disc has left its original position, but it can temporarily restore disc-oncyle relationship with during the mouth opening and closing movement [2].

In clinical treatment of TMD, the first choice is reversible conservative treatment [3]. Functional appliance is the more effective method. Functional appliance can guide the mandible forward and move the

displaced articular disc, reform the disc-condyle complex, and restore the internal anatomical structure of the temporomandibular joint.

Twenty-three patients (average age was 23.2 ± 4.7 years old) with disc displacement were selected. These patients were treated in the Orthodontics Department, the First Medical center of PLA General Hospital in Beijing from September 2022 to June 2024. All the patients were treated with functional appliance for 3 to 6 months. During the treatment, patients underwent specialist temporomandibular joint examination of MRI. SPSS V22.0 software was used to conduct paired t-test on the measured values before and after treatment, evaluate the treatment effect of the functional appliances on the disc displacement comprehensively.

After treatment, 89.4% of the clicking symptoms were relieved, 89.1% of the pain was eliminated, 76.2% of the mouth opening deviation degree was reduced. Normal movement of condylar accounts for 82.7% in DDwR. 92.1% of DDwR with joint effusion had no effusion after treatment. The disc-condylar angle and disc-condylar distance were reduced after treatment effectively. The rate of disk reposition in DDwR was greater than 80%, and in DDwoR was greater than 40%.

In summary, the functional appliance can improve the disc displacement, joint clicking, reduce the joint effusion effectively, and promote regeneration for early condylar absorption. The results of MRI analysis have shown that the functional appliance can significantly improve the structural disorder of TMJ. The treatment effect to DDwR of disc displacement is better than to DDwoR.

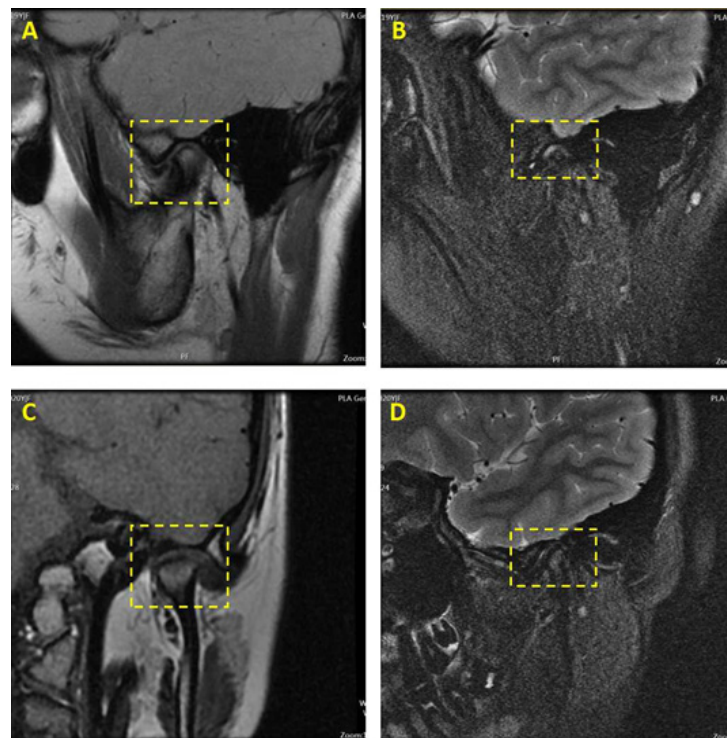


Figure 1: The MRI image of left TMJ. A and B was the pre-treatment image. C and D was the post-treatment image. Compared with A and B ,C and D showed reduced disc-condylar angle and disc-condylar distance effectively, less joint effusion after treatment.

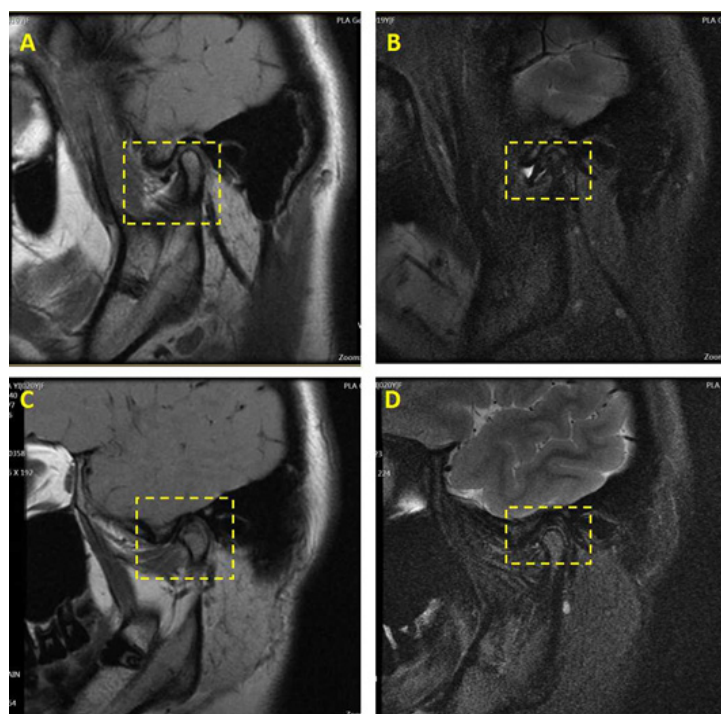


Figure 2: The MRI image of right TMJ. A and B was the pre-treatment image. C and D was the post-treatment image. Compared with A and B ,C and D showed reduced disc-condylar angle and disc-condylar distance effectively, no joint effusion after treatment.

References

1. Alexander Bergmann, Daniel Edelhoff, Oliver Schubert, Kurt-Jürgen Erdelt, Jean-Marc Pho Duc (2020) Effect of treatment with a full-occlusion biofeedback splint on sleep bruxism and TMD pain: a randomized controlled clinical trial. *Clinical Oral Investigations* 24: 4005-4018.
2. Yilin Jiang, Yajing Wang, Tianqi Wang, Dongqiao Liu, Chen Lin, et al. (2024) Orthodontic camouflage treatment of a hyperdivergent adolescent patient with anterior open bite and TMD: a case report. *BMC Oral Health* 24: 629.
3. Tong Lu, Li Mei, Bao-Chao Li, Zi-Wei Huang, Huang Li (2024) Hybrid treatment of varied orthodontic appliances for a patient with skeletal class II and temporomandibular joint disorders: A case report and review of literature. *World J Clin Cases* 2: 431-442.