



Does Vertebrobasilar Insufficiency Trigger some Psychiatric Disorders

Kadir Yıldırım¹, Aymer Coşar² and Mehmet Erkan Ustun^{3*}

¹Department of Neurosurgery, Kafkas University, Kars, Turkey

²Department of Neurosurgery, Yenimahalle Training and Research Hospital, University of Yıldırım Beyazıt, Ankara, Turkey

³Department of Neurosurgery and Anatomy, Private Clinic, Ankara, Turkey

Citation: Kadir Yıldırım, Aymer Coşar, Mehmet Erkan Ustun (2026) Does vertebrobasilar Insufficiency Trigger some Psychiatric Disorders. *J. of Psy Ins Review* 2(2), 01-03. WMJ/JPIR-131

***Corresponding author:** Mehmet Erkan Ustun, Department of Neurosurgery and Anatomy, Private Clinic, Ankara, Turkey.

Submitted: 26.02.2026

Accepted: 02.03.2026

Published: 12.03.2026

From 2016 to 2025 we operated 135 refractory vertebrobasilar insufficiency (VBI) patients [1-3]. After the operation we learned from the relatives or themselves of 20 patients that the psychiatric disorders that they have preoperatively resolved postoperatively. As this was an unexpected situation we did not evaluate the patients neuropsychologically at the preoperative period. Therefore we can not say quantitatively about the amount of improvement at the postoperative period. But the improvement of psychiatric disorders that was achieved after the operation for VBI and the high percentage of the recovery (over 88 %) of the VBI symptoms, lead us to decide if this observation may have a scientific basis.

The limbic system, also known as the paleomammalian cortex, is a set of brain structures involved in emotional processing and motivation in humans and many other animals [4]. Its various components support a variety of functions including emotion, behaviour, long-term memory and olfaction [5]. The limbic system is involved in lower order emotional processing of input from sensory systems and consists of the amygdala, mammillary bodies, stria

medullaris, central gray and dorsal and ventral nuclei of Gudden [6].

This processed information is often relayed to a collection of structures from the telencephalon, diencephalon, and mesencephalon, including the prefrontal cortex, cingulate gyrus, limbic thalamus, hippocampus including the parahippocampal gyrus and subiculum, nucleus accumbens (limbic striatum), anterior hypothalamus, ventral tegmental area, midbrain raphe nuclei, habenular commissure, entorhinal cortex, and olfactory bulbs [6-9].

The structures and interacting areas of the limbic system are involved in motivation, emotion, learning, and memory. The limbic system is where the subcortical structures meet the cerebral cortex [4]. The limbic system operates by influencing the endocrine system and the autonomic nervous system. It is highly interconnected with the nucleus accumbens, which plays a role in sexual arousal and the "high" derived from certain recreational drugs. These responses are heavily modulated by dopaminergic projections from the limbic system [10-12].

A great part of the limbic system have its vascular supply from vertebrobasilar system (VBS). So an insufficiency in VBS can easily lead to emotional and behavioural disorders. Among this 20 patients; 7 had depression, 6 had aggressivity, 5 had obsessive compulsive disorder (OCD) and 2 had panic disorder (PD). For the diagnosis of VBI we obtain cerebral and cervical computed tomographic (CT) or magnetic resonance (MR) angiography and brain CT or MR perfusion studies, beside brain MR investigation. Preoperative perfusion studies mainly show us the hypoperfused (ischemic) areas due to VBI and postoperatively the improvement in hypoperfused areas. In these 20 patients we retrospectively investigated the preoperative perfusion images, as postoperative studies were in normal range. Interestingly in the depression patients there were a less or more hypoperfusion at the left medial temporal lobe (Figure 1), whereas in the patients with aggressivity the hypoperfusion was at the right medial temporal lobe (Figure 2). Most interestingly in patients with OCD, the hypoperfusion was seen at both sides (Figure 3), while no hypoperfusion was seen in patients with PD. This may be either due to the less number of the patients or a hypoperfusion may be seen during the panic attack.

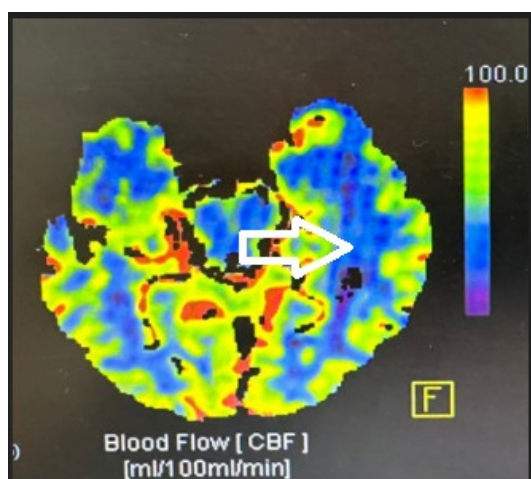


Figure1: White arrow Shows the Hypoperfusion at the left Medial Temporal lobe.

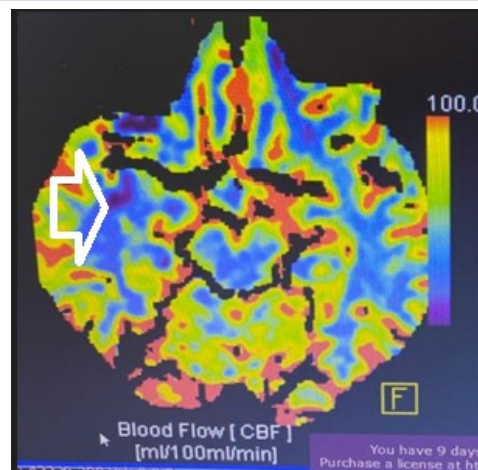


Figure 2: White arrow Shows the Hypoperfusion at the right Medial Temporal lobe.

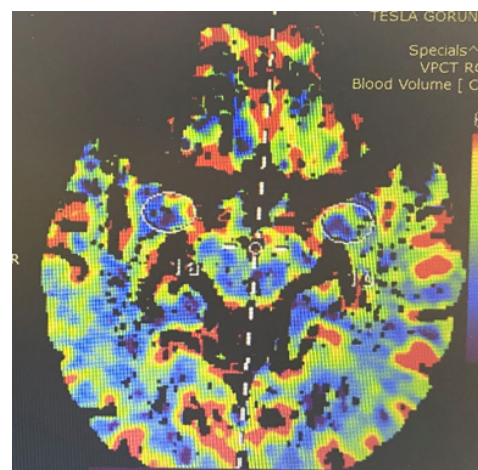


Figure 3: White elliptic Circles Show the Hypoperfused areas Bilaterally.

In the future we are planning to question the VBI patients for psychiatric disorders and if they have, then to apply neuropsychological tests also pre and postoperatively.

Author Contributions

Research conception and design: Kadir Yıldırım, Aymer Coşar, Mehmet Erkan Üstün. Data acquisition: Kadir Yıldırım, Aymer Coşar, Mehmet Erkan Üstün. Statistical analysis: Kadir Yıldırım, Aymer Coşar, Mehmet Erkan Üstün. Data analysis and interpretation: Kadir Yıldırım, Aymer Coşar, Mehmet Erkan Üstün. Drafting of the manuscript: Kadir Yıldırım, Aymer Coşar, Mehmet Erkan Üstün. Critical revision of the manuscript: Kadir Yıldırım, Mehmet Erkan Üstün. Supervision: Kadir Yıldırım, Mehmet Erkan Üstün.

Declarations

Ethics approval and consent to participate:

Approved by the institutional ethics committee Informed consent was obtained from all patients, and the ethics committee approved the study, documented under the approval number 2/12 dated 03.30.2022.

Consent for Publication

Obtained from all participants or their legal representatives.

Availability of Data and Materials

Data are available from the corresponding author upon reasonable request.

Competing Interests

The authors declare no competing interests.

Funding

This research received no specific grant from any funding agency.

Authors' Contributions

All authors contributed to study design, data interpretation, and manuscript preparation. All authors approved the final version.

References

1. Aymer Coşar, Kadir Yıldırım, Mehmet Erkan Üstün MD (2025) Is There A Subgroup of Kinking. Short Communication. World J Surg Surgical Case Rep 1: 57-60.
2. Efecan Cekic, Baylar Baylarov, Mehmet Besir Surme, Hakki Perk, Mehmet Erkan Ustun (2025) Collateral gains from vascular microsurgical intervention on the V1 segment dolicoarteriopathy of the vertebral artery: alleviating restless leg syndrome and urgency urinary incontinence symptoms in refractory vertebrobasilar insufficiency cases. Journal of Clinical Neuroscience 138.
3. Cekic E, Surme MB, Akbulut F, Ozturk R, Ustun ME (2024) Secondary Benefits of Microsurgical Intervention on the Vertebral Artery (V1 Segment) for Refractory Vertebrobasilar Insufficiency: Alleviation of Parkinsonism-Like Symptoms. World Neurosurg 187: e551-e559.
4. Schacter, Daniel L (2014) An episodic specificity induction enhances means-end problem solving in young and older adults. Psychology 29: 913-924
5. Morgane PJ (2005) A review of systems and networks of the limbic forebrain/limbic midbrain. Progress in Neurobiology 75: 143-60.
6. Catani M Dell'Acqua F, Thiebaut De Schotten M (2013) A revised limbic system model for memory, emotion and behaviour. Neuroscience and Biobehavioral Reviews 37: 1724-37.
7. Catani M, Dell'Acqua F, Vergani F, Malik F, Hodge H (2011) Short frontal lobe connections of the human brain. Cortex 48: 273-291.
8. Eichenbaum H (2007) Comparative cognition, hippocampal function, and recollection. Comparative Cognition & Behavior Reviews 2: 47-66.
9. Parkard MG (2009) Anxiety, cognition, and habit: A multiple memory systems perspective. Brain Research 1293: 121-128.
10. Sapolsky, Robert M (2003) Stress and Plasticity in the Limbic System. Neurochemical Research 28: 1735-1742.
11. Rolls, Edmund T (2015) Limbic systems for emotion and for memory, but no single limbic system. Cortex 62: 119-157.
12. Jin, Jingji (2015) Prefrontal-Hippocampal Interactions in Memory and Emotion". Front Syst Neurosci 9: 170.